Surgical Implications in a multi-variant third segment of the axillary artery

Daniel Ramos Alicea[1], Jordan Marcano-Anaya[1], John M. Pagan[2], Norman Ramírez[1,3] and Jailenne I. Quiñones-Rodríguez[1]*

[1]Department of Anatomy and Cell Biology, School of Medicine, Universidad Central del Caribe
[2]Plastic Surgery Section, San Jorge Children & Women's Hospital, San Juan, Puerto Rico
[3]Pediatric Orthopedic Department, Mayaguez Medical Center, Mayaguez, Puerto Rico

Email: 119dramos@uccaribe.edu

AMERICAN ASSOCIATION FOR ANATOMY

Program number:

Introduction

The third segment of the axillary artery (TSAA) contributes crucial irrigation to muscles in mostly all compartments of the upper limb. The posterior humeral circumflex artery (PHCA) is atypically found as a branch of the subscapular artery (SA) or as a single branch with the anterior humeral circumflex artery (AHCA) stemming from it.

We report three atypical branching patterns in the TSAA in which the subscapular artery gave rise to the posterior humeral circumflex artery and a second subscapular artery. Several anatomical variations have been reported with regards to the branches that the axillary artery gives, and they are proven to be of considerable clinical importance [1,2,3]. Details regarding deviation from the normal arterial pattern and variations of the axillary artery are crucial for anatomists, plastic and orthopedic surgeons, vascular radiologists, and interventional cardiologists.

Case Report

An atypical origin of the PCHA was observed, arising from the SA lateral to its origin **(Fig. 1)**. After its origin, the PCHA, which is accompanied by the axillary nerve, descended beneath the subscapularis towards the quadrangular space to supply the posterior shoulder joint and muscles. Another variation regarding the opposite medial side of the SA was identified. The subscapular artery revealed an unusual branch with an apparent course to irrigate the anterosuperior portion of the subscapularis. This branch, which we categorized as subscapular artery II (SAII), arising from the subscapular trunk at the same level of the PCHA variant. SAII then courses deeper medially into the axillary region and bifurcates in two branches to irrigate the subscapularis muscle **(Fig. 2)**. Following down to the thoracodorsal artery, an unusual pattern was observed regarding the irrigation of the latissimus dorsi muscle. Two horizontal branches horizontal branch I (HBI) and horizontal branch II (HBII) coming off the thoracodorsal artery were seen supplying the supero-medial fibers of the latissimus dorsi muscle.

Methods

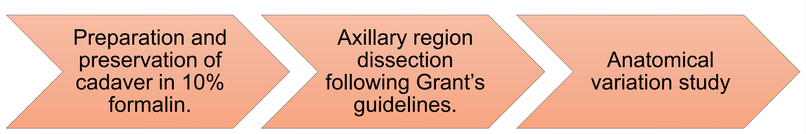

Acknowledgments

The authors would like to acknowledge the Department of Anatomy and Cell Biology from the Universidad Central del Caribe School of Medicine for the materials and funding for this project. Lastly, we would like to recognize our study's donors for enabling our study.

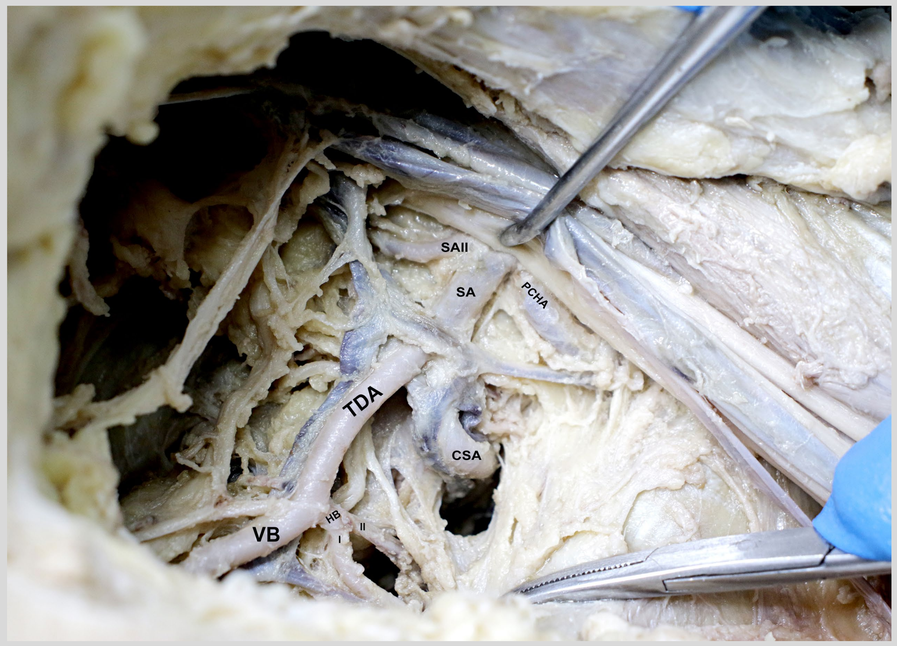

Figure 1. Atypical origin of the PCHA arising from the SA. TDA = Thoracodorsal Artery, SA = Subscapular Artery, SAII = Second branch of Subscapular Artery, PCHA = Posterior Circumflex Humeral Artery, CSA = Circumflex Scapular Artery, HB = Horizontal Branch, VB = Vertical Branch

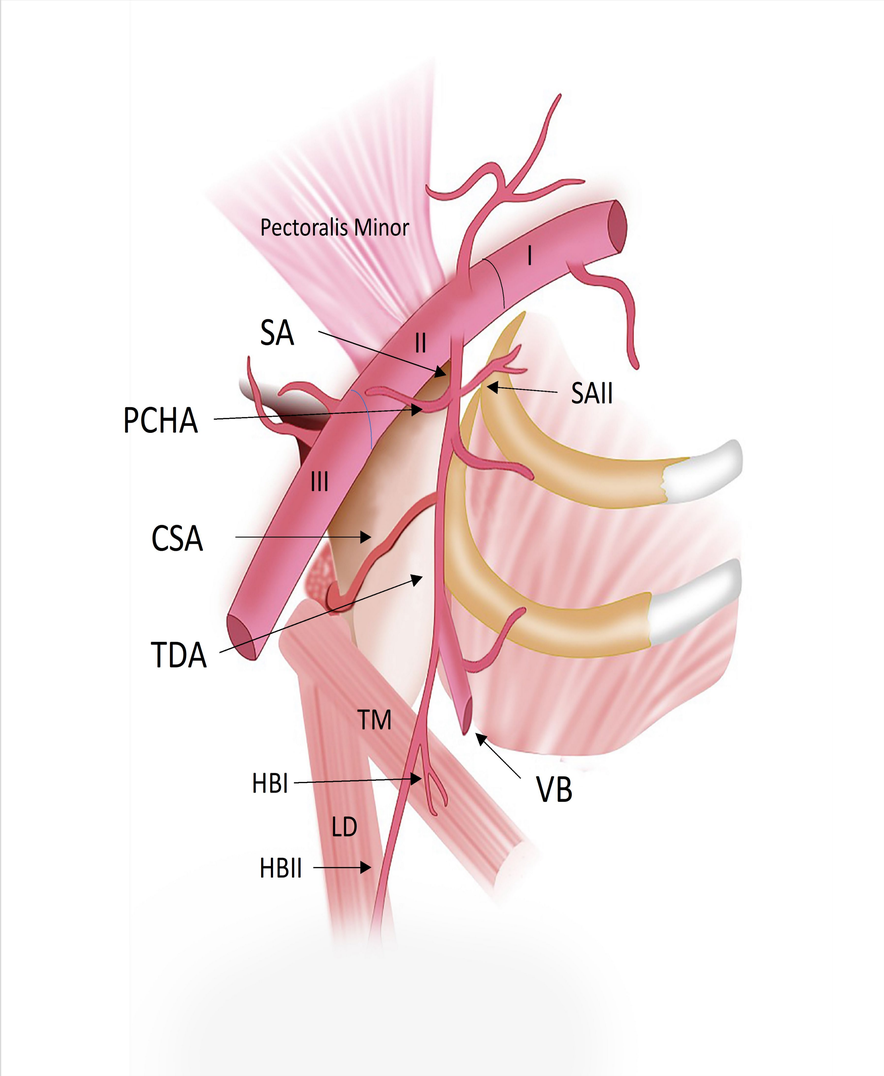

Figure 2 PCHA = Posterior Circumflex Humeral Artery, CSA = Circumflex Scapular Artery, TDA = Thoracodorsal Artery, TM = Teres Minor, LD = Latissimus Dorsi, VB = Vertebral Branch, HB = Horizontal Branch, SA = Subscapular Artery

Discussion

Anatomical variations have been reported regarding branches that the axillary artery gives, and they are proven to be of considerable clinical importance [1]. Failure to identify variant anatomy is a commonly cited technical error in surgical injuries, even among experienced surgeons. [2]

In plastic surgery, variant TDA's can increase the risk of failure of latissimus dorsi flap procedures (LDFP) performed by plastic surgeons. Especially since surgeons start with defect analysis, in which they observe the area requiring reconstruction for vascular status. As this procedure relies on preserving the vasculature of the transplanted tissue, surgeons may use arterial imaging to avoid transplant failure; which has been used for examining arterial branching patterns before tissue flap repair. [3]

In our case, the cadaver exhibits a variant PCHA stemming from the SA. Studies have reported that variations in this artery are implicated in a higher risk of vessel damage such as in the case of Quadrilateral Space Syndrome. [4] This can lead to thrombosis and aneurysm of the vessel. Furthermore, a variant PCHA may be damaged in humeral fracture-dislocations and during rotator cuff surgery.

Additionally, a previously undescribed SAII might impose a surgical obstacle in the case of thrombotic occlusion or traumatic damage. Poor use of arterial imaging prior to surgeries might lead to suboptimal interventions.

Conclusion

Anatomical variants, not only in the axillary artery but in the whole body, have remarkable importance in surgery as a whole and are a cause of the continuous adjustment of surgical standards and patient management. In our case, an unreported multi-variant TSAA should draw the attention of medical specialties such as orthopedic and plastic surgeons. Such findings should increase the need for preoperative vascular imaging. As a result, the characterization of newly discovered vascular variants is crucial for interventional physicians to improve surgical outcomes and prevent iatrogenic injury.

References

1. Yang K, Lee H, Choi IJ, et al. Topography and Anatomical Variations of the Axillary Artery. *Biomed Res Int*. 2021;2021:6393780. Published 2021 May 24. doi:10.1155/2021/6393780

2. Katarzyna A. Kowalczyk, Adrianna Majewski, Analysis of surgical errors associated with anatomical variations clinically relevant in general surgery. Review of the literature, Translational Research in Anatomy, Volume 23, 2021.

3. Yang ZB, Niu JD, Ma Y, Li JN, Shen JY, Yao M. [Clinical application of computed tomography angiography and three-dimensional reconstruction in repairing high-voltage electrical burn wounds in necks, shoulders, axillas, and upper arms with tissue flaps. 2018;34(12):874-880. doi:10.3760/cma.j.issn.1009-2587.2018.12.011

4. Hangge P, Breen I, Albadawi H, Knuttinen M, Naidu S, Oklu R. Quadrilateral space syndrome: Diagnosis and clinical management. J Clin Med. 2018;7(4):86.