The Relevance of the Adamkiewicz Artery Anatomical Variations for Resection of Spinal Tumors

Luis R. Navedo-Sánchez[1], Cheysaliz Pérez-Verdejo[1], Caleb Feliciano[2], Rafael Rodríguez-Mercado[2], and Jailenne I. Quiñones-Rodríguez[1]*

[1]Department of Anatomy and Cell Biology, School of Medicine, Universidad Central del Caribe, Bayamón, Puerto Rico
[2]Department of Surgery: Neurosurgery Section, University of Puerto Rico Medical Sciences Campus, San Juan, Puerto Rico

Program Number: 784.6

Email: 119lnavedo@uccaribe.edu

Introduction

The spinal cord is a critical structure that provides the functioning of many areas of the body. It contains the sensory and motor neurons responsible for the functioning of the human body**.** This structure is prone to lesions, which results in a wide range of symptoms, depending on the area of the insult. Knowledge about the irrigation of the spinal cord is important for therapeutic planning of A common etiology of spinal cord lesions is associated with its vasculature.

The artery of Adamkiewicz originates from the thoracic and abdominal aorta, specifically arising from a spinal branch of either one of the lower posterior intercostal arteries (T9-T11) [1], from the subcostal artery (T12), or less frequently of the upper lumbar arteries (L1-L2), most commonly on the left side [1]. The AKA being a major branch, carries a significant supply of perfusion for the lower spinal cord, and is an important supply to the anterior spinal artery along with the spinal cord's lower thoracic, lumbar, and sacral segments [2]. Its preservation results in preventing iatrogenic injury to these segments. Clinical variations can be described by gender, geographical origin and varies by segment of spinal nerves.

Methods

PubMed literature search with the following keywords: "Variation Adamkiewicz".

Selected additional filter parameters, the next being: "Results by year ranging from 2016-2021 (5-year period), Article type: "Review, Systemic Review, Books and Documents, and Meta-Analysis," Language: "English."

Without additional filter other than timeline yielded 12 manuscripts; of these, only three were selected based on our goals.

Hypothesis

Knowledge about the anatomical variations of the AKA is crucial during neuro surgical interventions since ligation of this vessel during anterior spine instrumentat ion might significantly reduce the blood supply to the cord. For instance, preoperative approaches including novel imaging techniques to the thoraco-lumbar spine will decrease neurovascular implications of the spinal cord.

Acknowledgments

The authors of this case report would like to acknowledge the Universidad Central del Caribe School of Medicine (UCCSoM) and the Anatomy and Cell Biology Department for giving us the funding to conduct this study.

Results

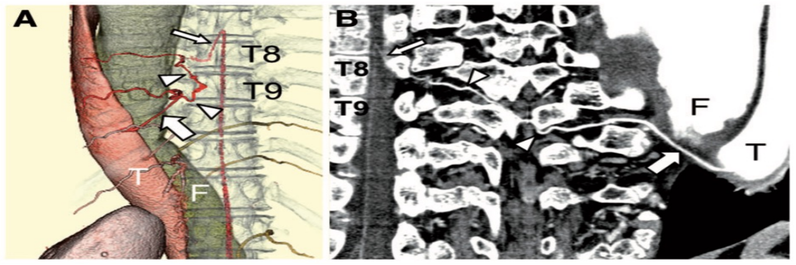

Figure 1 (A) 3D volume-rendered image, shows the collateral circulation to the artery of AKA (small arrow), which originates from the occluded L8th ICA via the muscular branch (arrowheads) from the L9th ICA (large arrow). The L9th ICA originates from the true lumen (T). (B) Curved planar reformatted image shows continuity of the T of the aorta, the L 9th ICA (large arrow), the muscular branch (arrow heads), and the AKA (small arrow). F: false lumen [4].

Results

Author and year	AKA Anatomical Variations
D. Taterra et al. 2019	• They performed a metanalysis study to evaluated the prevalence by biological sex and geographical origin of AKA (n=5437 patients). • They showed that the AKA was slightly more prevalent in males than females; however, the difference between biological sex was not significant. • From a geographical origin perspective, the presence of the AKA was most prevalent in the Netherlands, followed by France, Japan and the USA.
U. Heber et al. 2020	• They aimed to evaluate the spinal cord's epidural intraspinal collateral blood supply. • They highlighted the importance of preserving collateral flow by preserving major branches during any kind of open or endovascular therapy.

Table 1. Current articles exploring alternative techniques for the location and identification of AKA

Author and year	Innovative techniques to identify AKA anatomical variations
Yin et al. 2016	• Explored if optimal monochromatic reconstruction could improve the depiction of the AKA on gemstone spectral computed tomographic angiography (GSCTA) compared with the polychromatic reconstruction protocol. • They demonstrated that the image quality was significantly improved markedly by optimal monochromatic reconstruction, including uniform particles and the sharp edge of the artery.
Yoshioka K, Niinuma H, Ohira A, et al. 2017	• Investigated the collateral circulation to the artery of Adamkiewicz using Multidetector row computed tomography (MDCT) • They found that visualization of the artery of Adamkiewicz and its collateral circulation in the sample had an average visualization score of 2.8 ± 0.6.
Saiki Y, Watanabe K, Ito K, et al. 2019	• Developed a system that directly monitors the cerebrospinal fluid temperature (CSFT) and differential selective hypothermic intercostal artery perfusion (ICA) using cold blood (D-HIAP) to determine any changes in spinal cord perfusion. • They showed that 84.8% of patients which required reconstruction of an intercostal artery had early patency rates, which gave several reconstructed ICA of 2.0 ± 1.2 per patient.

Table 2. Current articles exploring alternative techniques for the location and identification of AKA

Discussion

We aimed to highlight the most common anatomical variations of this artery and various techniques available capable of determining its location preoperatively, this due to its clinical significance in neuroanatomy, and the planning of neurosurgical interventions. For this purpose, we analyzed the results of multiple publications. The variations analyzed were limited to the number of arteries (AKA) per subject, origin side of the AKA, anatomical segment origin of AKA, continuity of AKA, and morphometric analysis of AKA **(Table 1)**. In addition, we described relevant imaging studies and techniques used to localize the AKA, it's collateral circulation, distribution and described the outcomes of damaging the artery or its collateral circulation **(Table 2)**.

One of the most notable findings was the significant CSFT drop served to detect the disparity in temperature between the intrathecal space and blood generated by D-HIAP revealed individual variability in CSFT changes and the complexity of the spinal cord perfusion. Using this technique intraoperative may help identify the major blood supply for spinal cord perfusion and underlying collateral network [3]. Subsequently, another group showed the use of a multidetector-row computed tomography to assess the collateral circulation of AKA as a promising preoperatively tool for conservation and reduction of iatrogenic injury to the AKA and, as a result of ischemic injury to the spinal cord during surgery **(Fig. 1)** [4]. By using this technique preoperatively, the localization of the AKA could be maximized and, with it, reducing the number of iatrogenic injuries during surgical intervention.

Further studies on neurovascular variations should be encouraged because the preservation of neurovascular structures is relevant for the protection of the spinal cord and the maintenance of its function in this type of intervention.

Conclusion

This study aimed to highlight the importance of neurovascular anatomical variations to understand spinal cord irrigation, which is essential for the therapeutic planning of neurosurgical implications. By using imaging techniques such as MDCT preoperatively, the localization of the AKA could be maximized and, with it, reducing the number of iatrogenic injuries during surgical intervention.

References

1. Carmichael SW, Gloviczki P. Anatomy of the blood supply to the spinal cord: The artery of Adamkiewicz revisited. *Perspectives in Vascular Surgery and Endovascular Therapy*. 1999;12(1):113-122.
2. Lindeire S, Hauser JM, Anatomy, Back, Artery of Adamkiewicz. [Updated 2021 Aug 1]. In: StatPearls [Internet]. Treasure Island (F) StatPearls Publishing; 2021 Jan
3. Saiki Y, Watanabe K, Ito K, et al. Differential selective hypothermic intercostal artery perfusion: a new method to probe spinal cord perfusion during thoracoabdominal aortic aneurysm repair. *Gen Thorac Cardiovasc Surg*. 2019;67(1):180-186.
4. Yoshioka K, Niinuma H, Ohira A, et al. Mr Angiography and CT angiography of the artery of Adamkiewicz: Noninvasive preoperative assessment of thoracoabdominal aortic aneurysm. *RadioGraphics*. 2017;23(5):1215-1225.
5. 13. Yin XR, Xia W, Yao ZW, He HJ, Feng XY. The Initial Exploration of Adamkiewicz Artery Computed Tomographic Angiography with Monochromatic Reconstruction of Gemstone Spectral Imaging. J Comput Assist Tomogr. 2016;40(5):820-826.
6. 4. Heber UM, Mayrhofer M, Gottardi R, et al. The intraspinal arterial collateral network: a new anatomical basis for understanding and preventing paraplegia during aortic repair. Eur J Cardiothorac Surg. 2021;59(1):137-144.