Unusual Nervous Contribution to the Formation of the Inferior Gluteal Nerve: Clinical and Surgical Outcomes

María A. Portela-Vázquez[1], Alexandra N. Acevedo-Arroyo[1], Marizabel La Puerta-Resto[1], Sofía Jiménez-Dietsch[1], Jailenne I. Quiñones-Rodríguez[1]

[1]Department of Anatomy and Cell Biology, Universidad Central del Caribe, School of Medicine

Email: 119mportela@uccaribe.edu

Abstract

Knowledge of anatomical variations within the gluteal region is important to accurately diagnose and avoid potential iatrogenic nerve injuries. An unusual nerve course within the gluteal region was identified. The posterior femoral cutaneous nerve (PFCN) and S3 nerve root contributed to the formation of the inferior gluteal nerve (IGN), which then continued its path to innervate the gluteus maximus muscle (GMax). Based on these findings, the IGN received fibers from spinal levels L5, S1, S2 and S3. This variation has clinical and surgical implications. Peripheral nerve anomalies are important for physicians and should be taken into consideration for some radiological diagnoses and surgical procedures such as total hip arthroplasty which is the most common surgical procedure in which the IGN can be injured.

Case Report

During a gross cadaveric dissection session for first-year medical students held at the Department of Anatomy and Cell Biology, Universidad Central del Caribe, School of Medicine (UCC – SoM), a unilateral variation of the IGN was identified in an elderly female Puerto Rican. The clinical history, family history, and cause of death were not available. Gluteal region dissection was performed following Grant's Dissector. Initially skin incisions were made, followed by removal of the superficial and deep fascia revealing the GMax muscle. Medial incision through de GMax muscle was made, flaps were exposed to identify underlying structures. Examination of the right gluteal region revealed the Gluteus medius (GM) and PM, an important anatomical landmark. Lateral and inferior to the PM, the SN was observed exiting the pelvis and inserting the gluteal region through the greater sciatic foramen. Medial and inferior to the PM, the PFCN accompanied the S3 root (Figure 2). Both the PFCN and S3 root contributed to the formation of the IGN which then proceeded its course to innervate the GMax muscle without further anatomical variation (Figure 2).

Methods

During a gross cadaveric dissection, an anatomical variation was found in an elderly adult male cadaver with an unusual nerve course within the gluteal region. The body was preserved in 10% formalin and dissected following the guidelines in Grant's Dissector, 16th edition.

Acknowledgments

The authors of this case report would like to acknowledge the Department of Anatomy at the Universidad Central del Caribe School of Medicine (UCCSoM) for giving us the opportunity to conduct this study. Lastly, we are thankful for the body donors who have gifted their bodies to medical science.

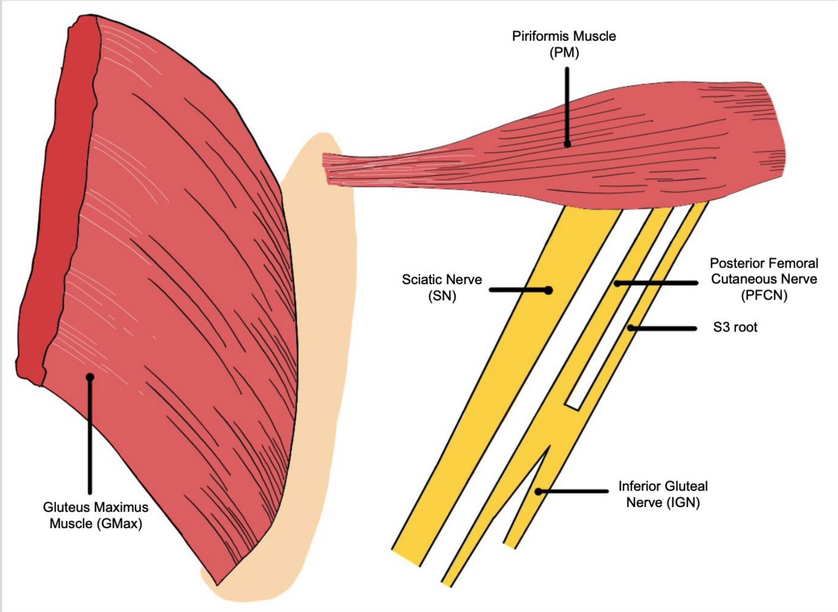

Figure 1. Illustration showing the findings in the right gluteal region presented in the case report. The Posterior Femoral Cutaneous Nerve (PFCN) and S3 contribute to the formation of the Inferior Gluteal Nerve (IGN) which then follows its course to innervate the Gluteus Maximus (GMax)

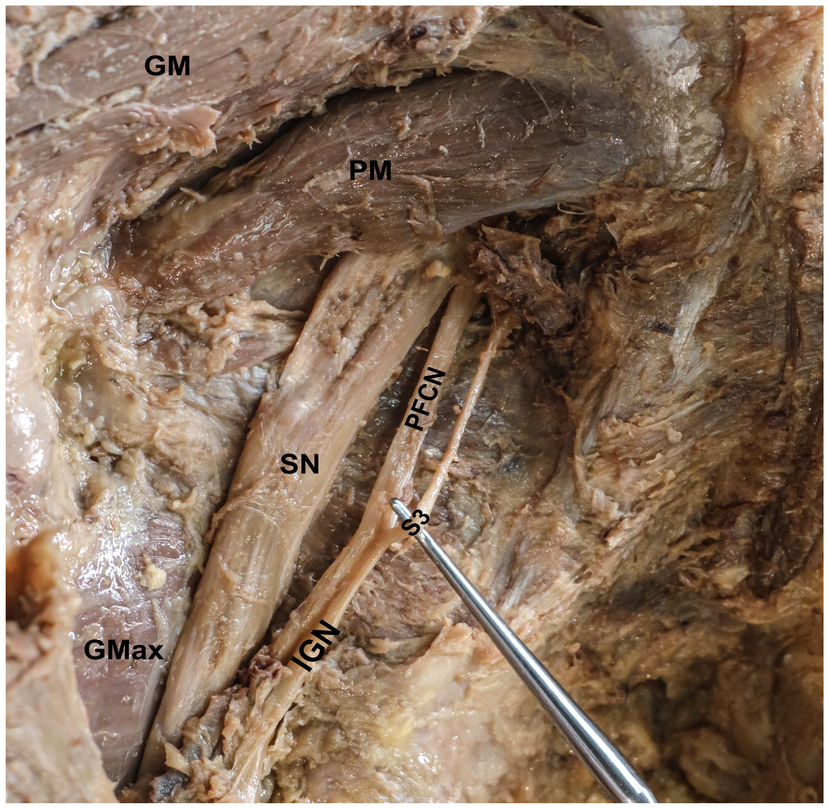

Figure 2. Dissection of the left gluteal region showing the unusual contribution of the Posterior Femoral Cutaneous Nerve (PFCN) and S3 nerve root (S3) to the Inferior Gluteal Nerve (IGN). GM: Gluteus Medius; PM: Piriformis Muscle; SN: Sciatic Nerve; PFCN: Posterior Femoral Cutaneous Nerve; S3: S3 nerve root; IGN: Inferior Gluteal Nerve; GMax: Gluteus Maximus

Discussion

The IGN normally originates inferior to the PM from the anterior rami of L5-S2 nerves, exiting the pelvis via the greater sciatic foramen dividing into multiple branches that supply the GMax muscle. However, variations in this nerve have been reported. Variations include a high division of the sciatic nerve where an anomalous double root that emerged from the upper and lower borders of the PM forms the IGN. While Yan et al. reported the emergence of the IGN and vessels from the upper edge of the PM in the Japanese population. In another case, Kotian et al. reported a communicating plexus between the PFCN and IGN which then terminated in the gluteal region. In the present case, we report an atypical nervous contribution to the IGN. The IGN arises from the PFCN and S3 nerve root, which are seen exiting the pelvis medial and inferior to the PM. These findings suggest the IGN is receiving fibers from spinal levels L5, S1, S2 and S3. These peripheral nerve variations can be due to molecular incoordination of myogenesis or axonal guidance during development. After growth cone formation, variations in expression of numerous factors determine the direction of a nerve and can therefore result in nerve anomalies. These factors include netrins, slits, ephrins etc.

Injury to the inferior gluteal nerve is most commonly iatrogenic in origin, primarily from pelvic pathology, intramuscular injection-related injury and surgical interventions. Total hip arthroplasty is the most common surgical procedure in which the IGN can be injured, with the posterior approach carrying the greatest risk. While the incidence of damage to the IGN remains unknown, the incidence of injury to peripheral nerves during hip replacement ranges from 0.5 to 8%. Susceptibility to injury of the IGN during total hip arthroplasty may be explained by its close relationship to the deep surface of the gluteus maximus where it can be damaged before observed. Injury by these means can result from direct trauma, vascular damage or due to stretching and retraction with surgical instrumentation. Other instances in which the IGN can be involved are entrapment via piriformis syndrome and peri-sacral surgery. IGN entrapment is a rare cause of low back and buttock pain. When the PM entraps it, the resulting pain is often misdiagnosed as myofascial pain which can delay appropriate treatment. Key complications of IGN injuries are alteration of the gait cycle or gluteus maximus 'lurch' due to weakness and ipsilateral muscle wasting that leads to loss of the defined muscle shape, both which can affect quality of life. While the IGN has been described to supply mainly motor innervation to the GMax, the variation that we describe suggests that this nerve could be receiving somatosensory innervation through the PFCN.

We propose that this sensory contribution to the IGN, if lesioned or damaged, can lead to somatosensory consequencessuch as anasthesia, paraesthesia, hypaesthesia, hyperaesthesia and pain in the region of the buttocks and posterior thigh. Identification of the IGN and its possible variations as sources of neurogenic pain can aid clinicians in diagnosis and management of gluteal pain syndromes due to lesions or iatrogenic damage during surgical procedures.

Conclusion

Understanding anatomical variations in the gluteal region is vital for clinicians during administration of intramuscular injections, assessment of gluteal pain with variable symptoms and for orthopedic surgeons during hip surgery. The IGN provides motor innervation to the GMax muscle and is prone to iatrogenic injury and entrapment, leading to pain, muscle weakness and even alterations in gait motion. Normally arising from the anterior rami of spinal nerve roots L5-S2, we report a variation in the origin of the IGN where it arises from the PFCN and the S3 root of the sacral plexus. We propose that the sensory innervation by the PFCN to the IGN can lead to somatosensory repercussions if damaged or lesioned. Also, iatrogenic damage during surgical procedures due to unforeseen variations may lead to complications that affect the post-operative course, pain management and the rehabilitation phase. Detailed description of these anatomical variations can assist physicians and surgeons during diagnosis and management of gluteal region syndromes and decrease the risk of iatrogenic injuries.

References

1. Paval J, Nayak S. A case of bilateral high division of sciatic nerve with a variant inferior gluteal nerve. *Neuroanatomy*. 2006.
2. Yan J, Takechi M, Hitomi J. Variations in the course of the Inferior gluteal nerve and artery: a case report and literature review. *Surgical Science*. 2013 Oct 1;4(10):429.
3. Kotian SR, D'Souza AS, Shamshudheen S, Sangeetha C, Sumalatha S. Multiple anomalous variations in the gluteal region. Online J Health Allied Scs. 2014;13(3):5.
3. Iwanaga J, Simonds E, Vetter M, Patel M, Oskouian RJ, Tubbs RS. The inferior gluteal nerve often has a cutaneous branch: A discovery with application to hip surgery and targeting gluteal pain syndromes. *Clin Anat*. 2018.